

# Management of Epistaxis

Richard Douglas

Gillies, Auckland and North Shore Hospitals

The University of Auckland  
New Zealand

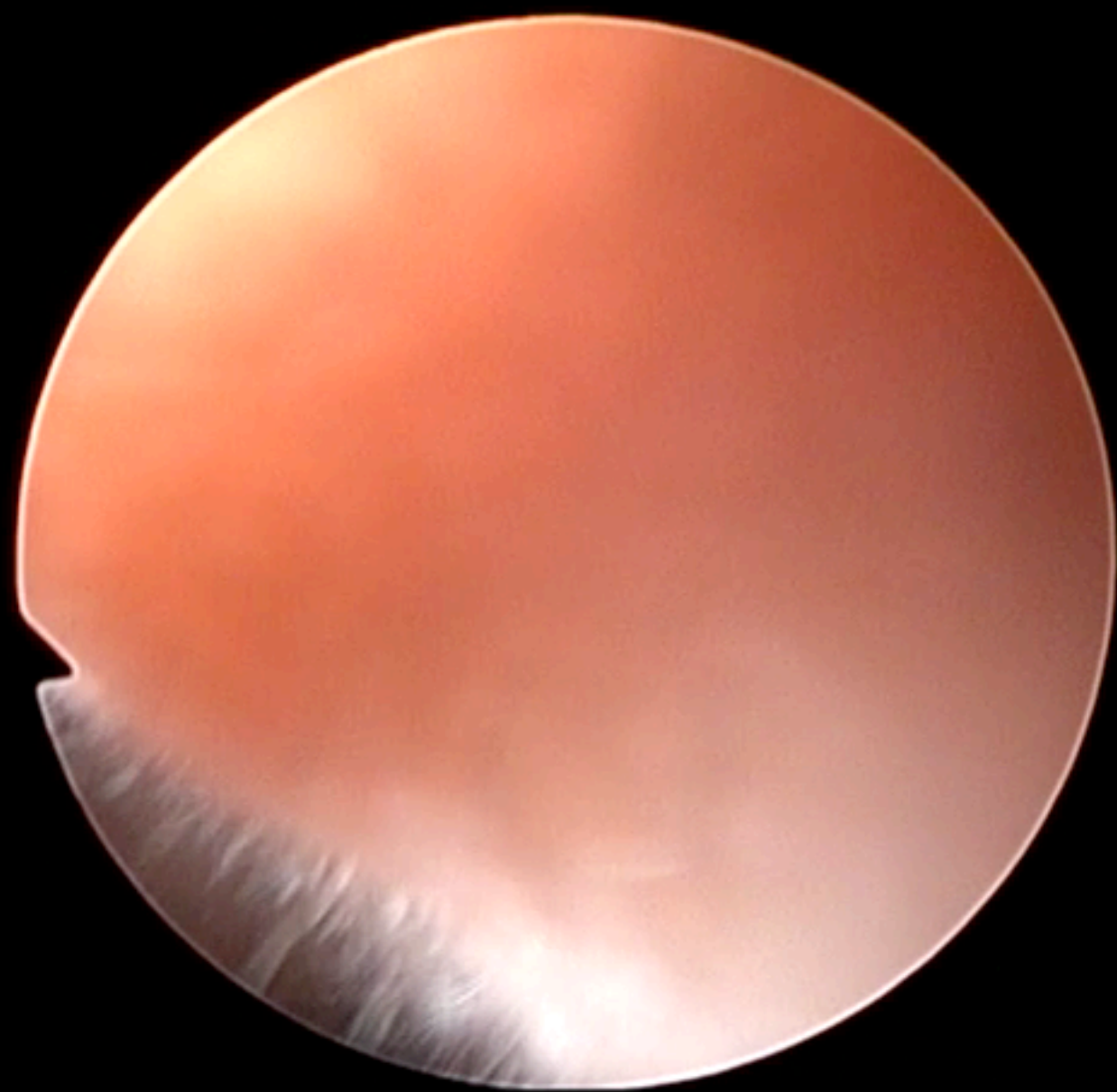




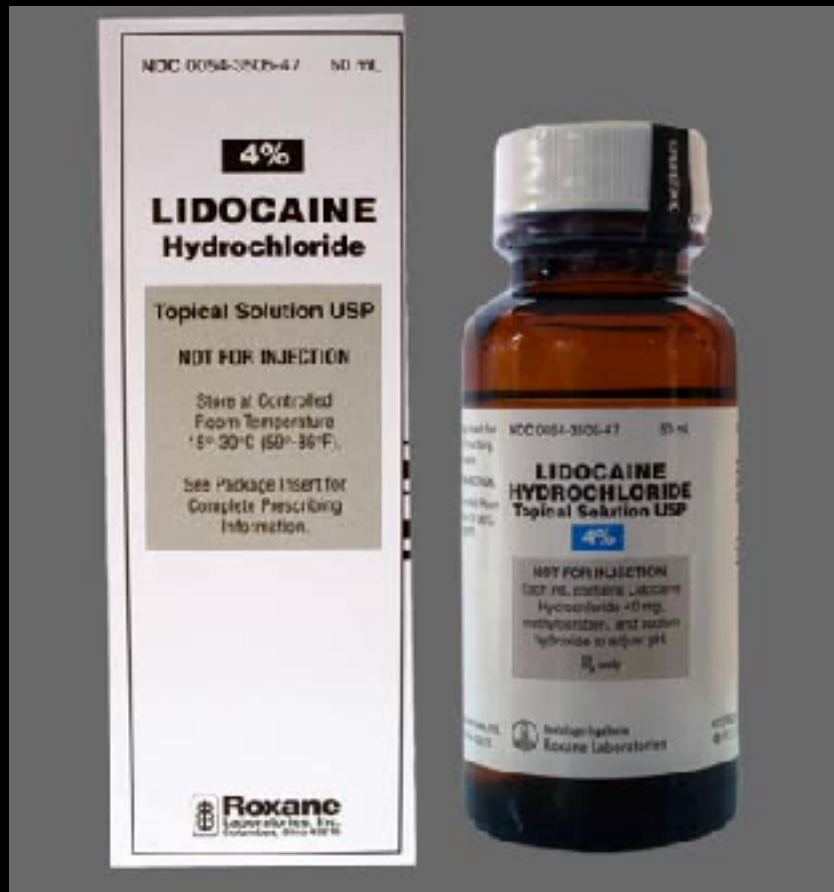# Case 1


15 year old student

recurrent epistaxes right side

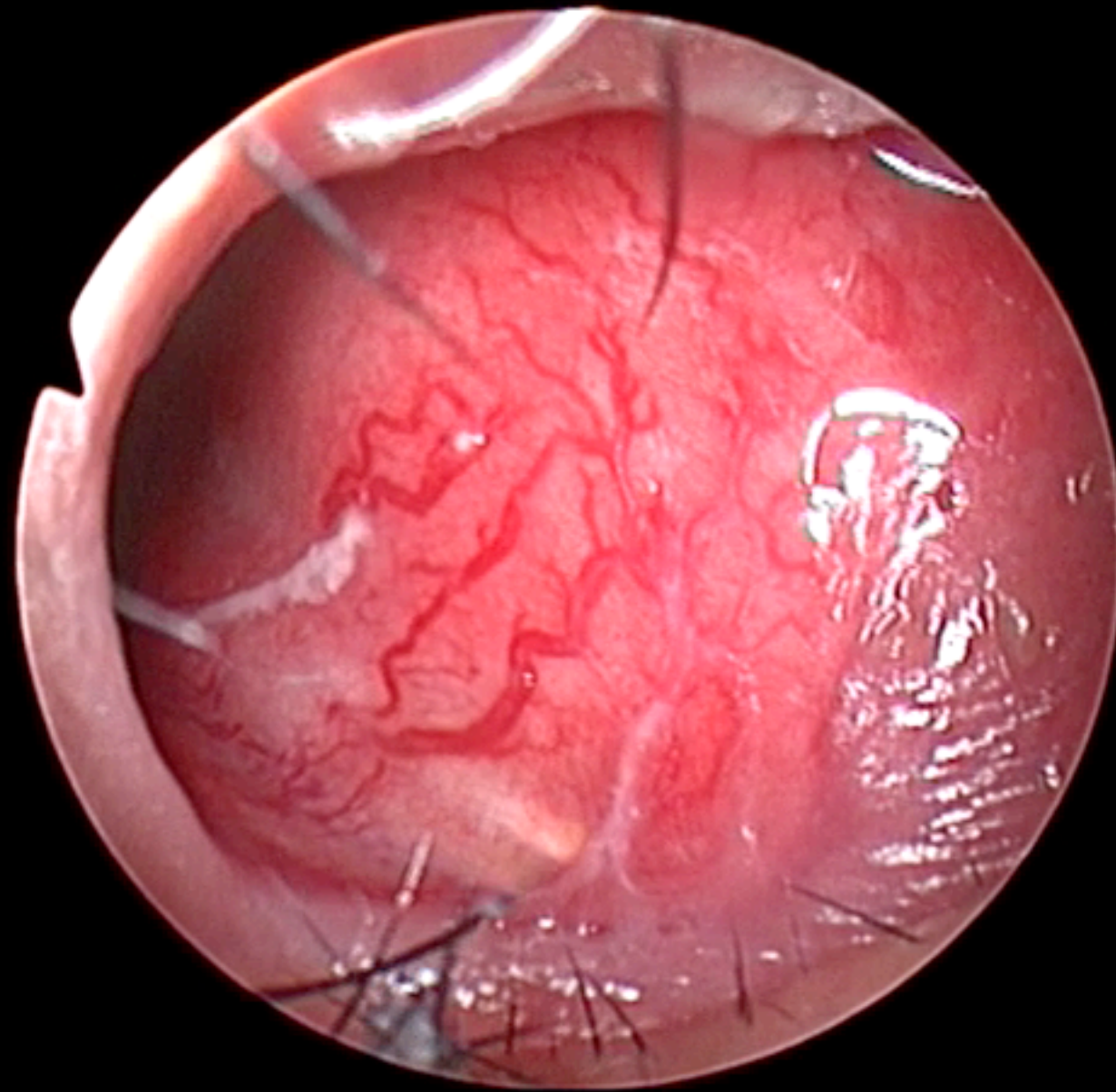


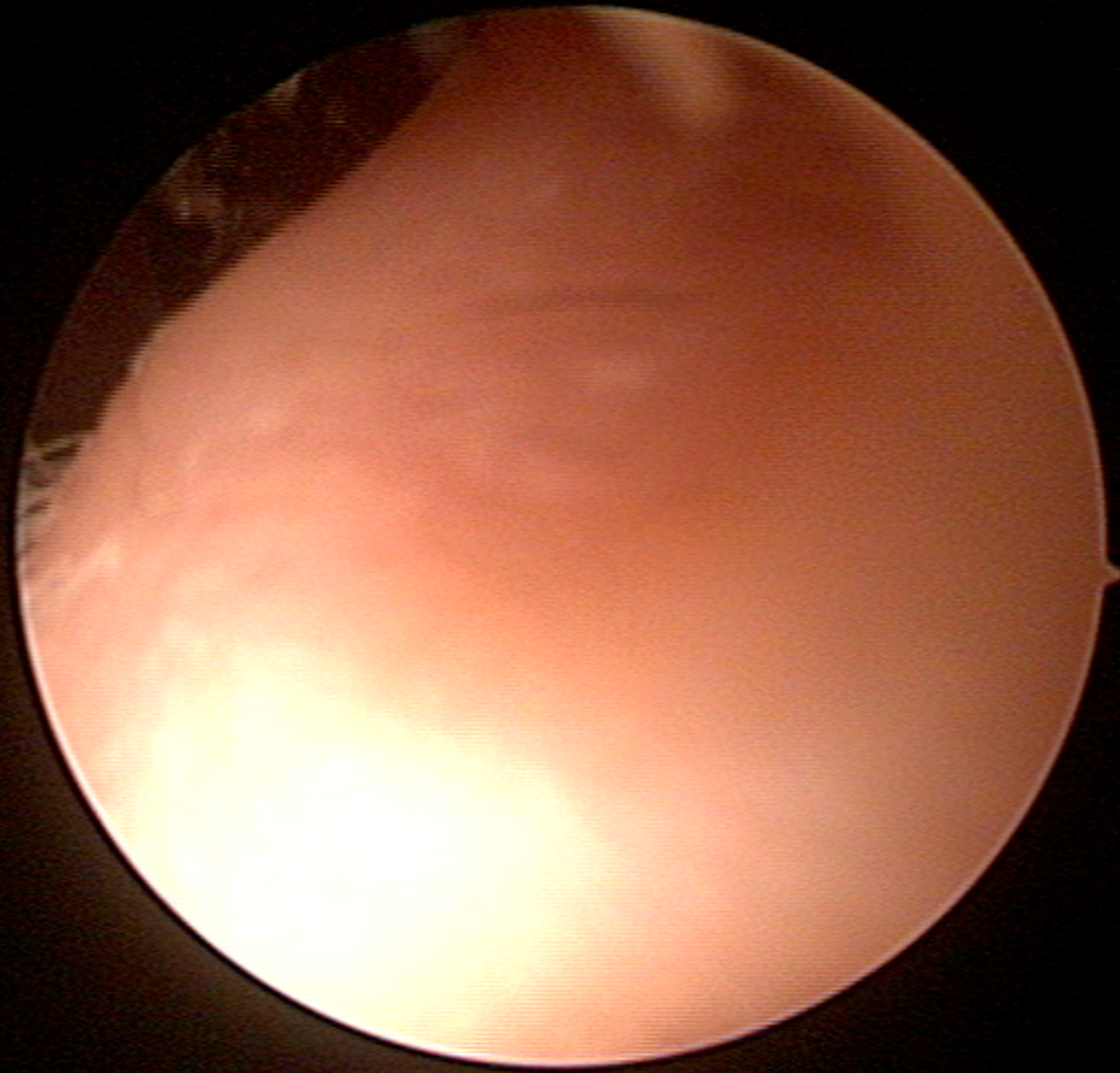












fucidic acid ointment for two weeks

## Case 2

55 year old woman

recurrent epistaxes right side

atrial fibrillation

dabigatran

reassure

measure heart rate and BP

pack with vasoconstrictor/LA mix

clean up



**MOTHER'S LITTLE HELPER**  
**LADY JANE**  
**the rolling stones**



*LONDON*

45-902







WV3

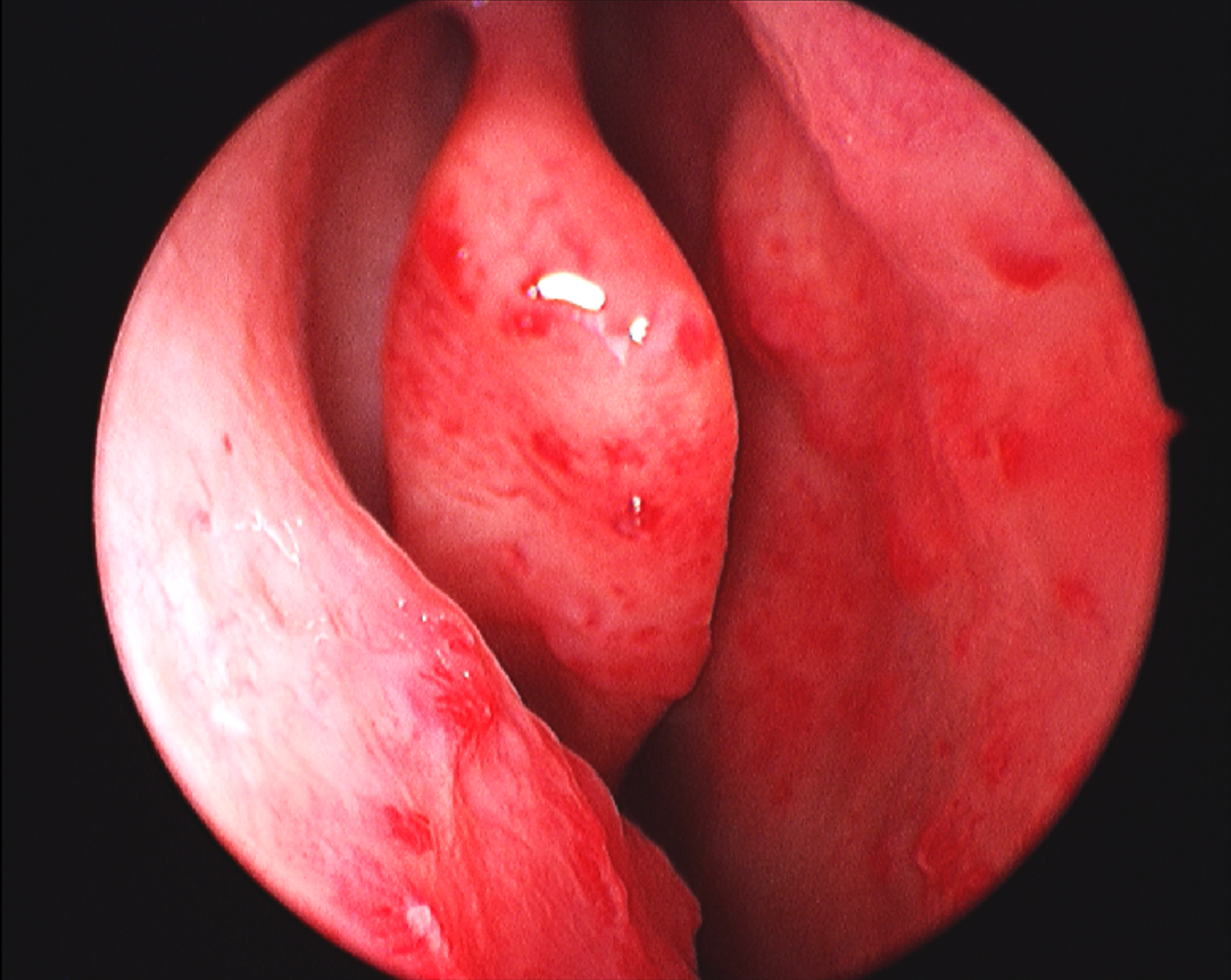


congenital - haemophilia, HHT

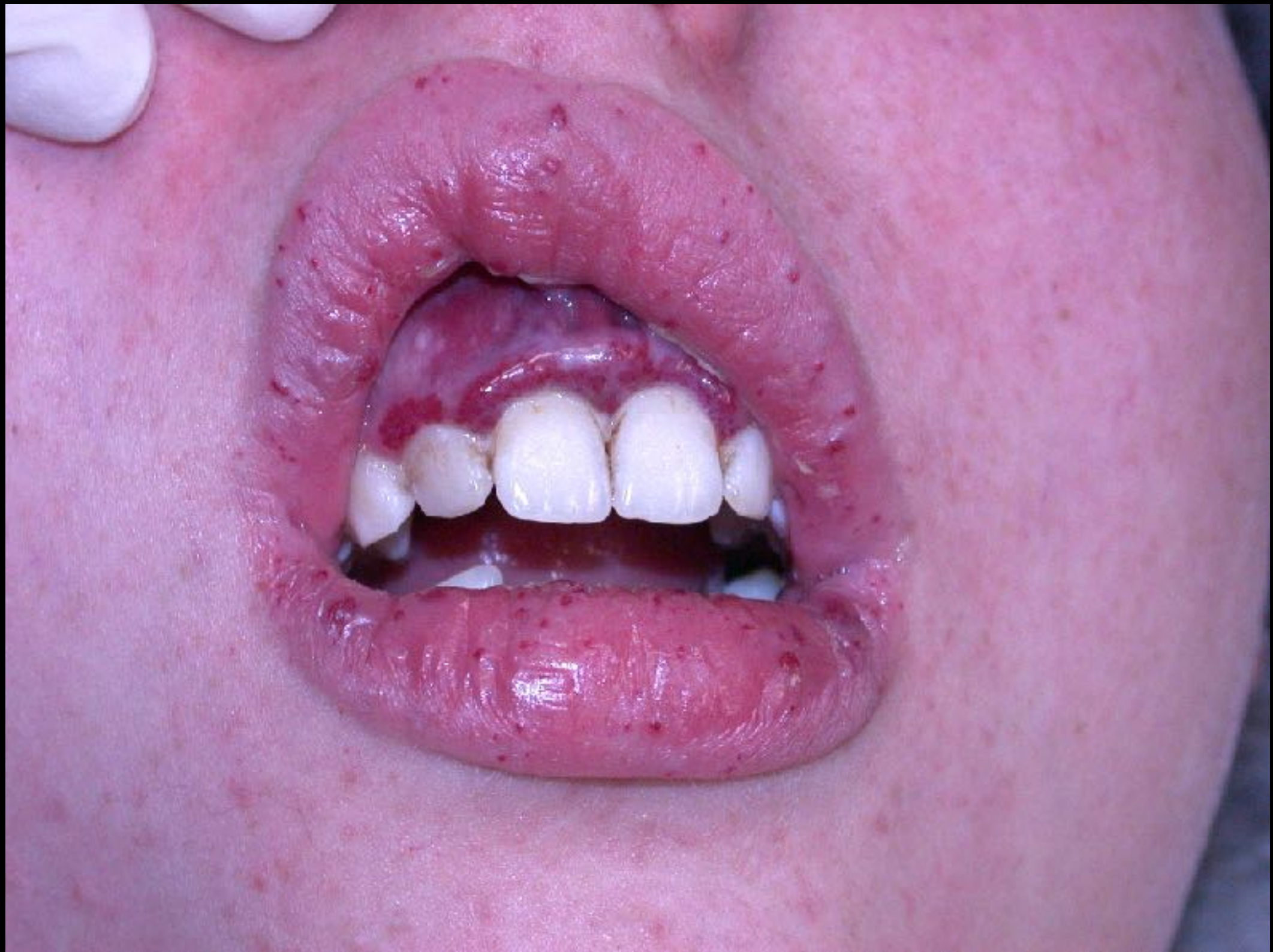acquired

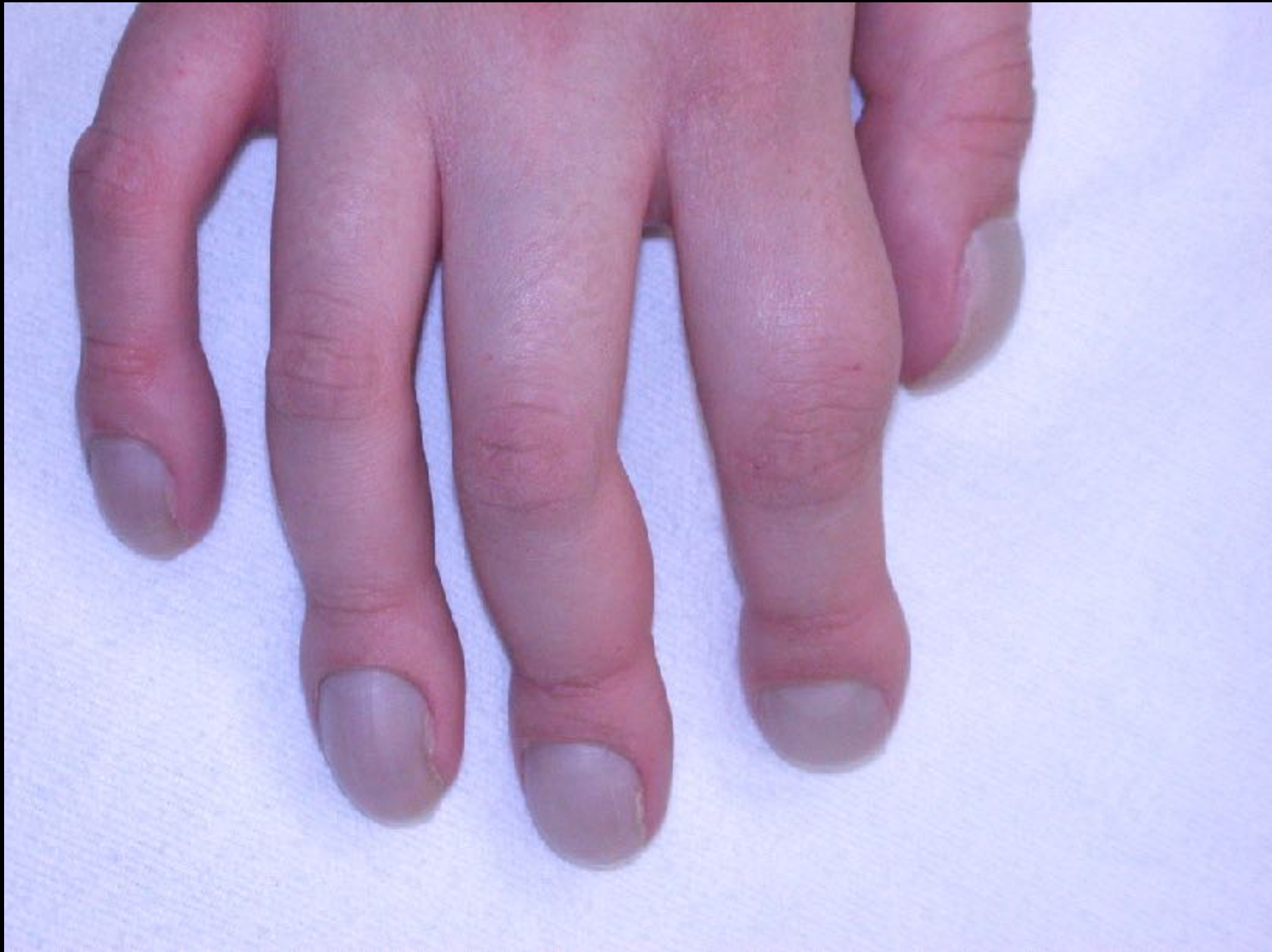anticoagulants - aspirin, warfarin, ticlopidine

thrombocytopenia

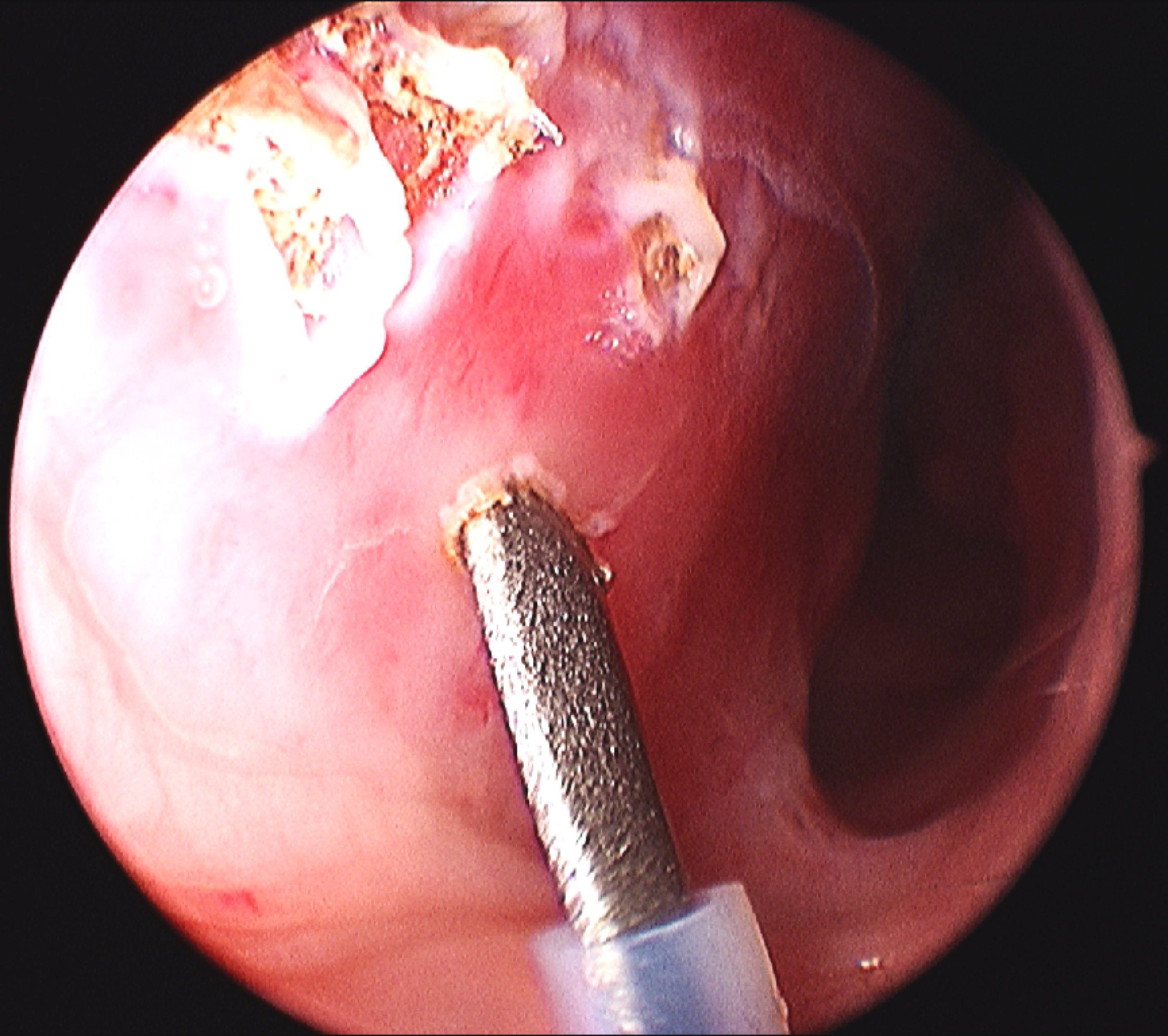




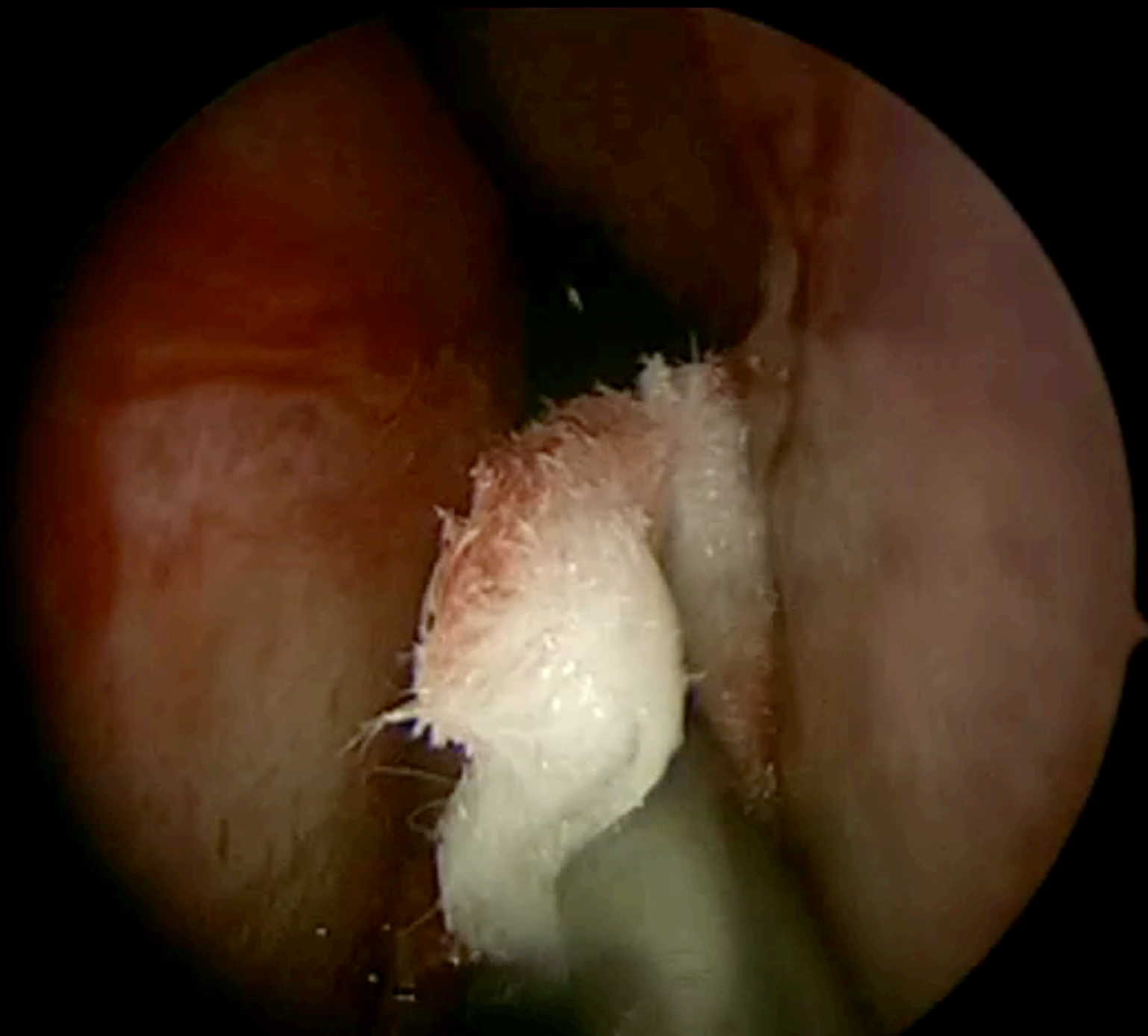




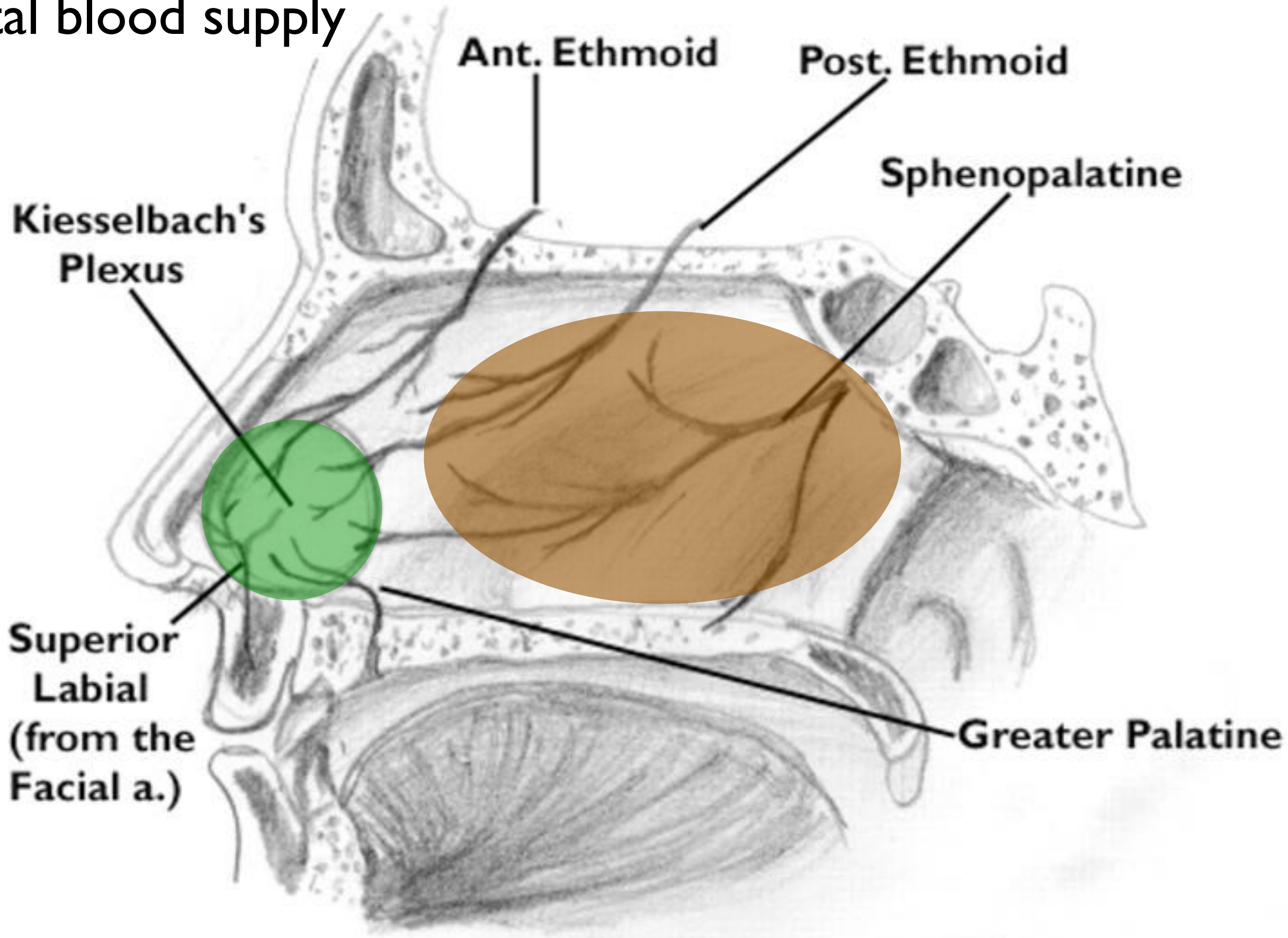






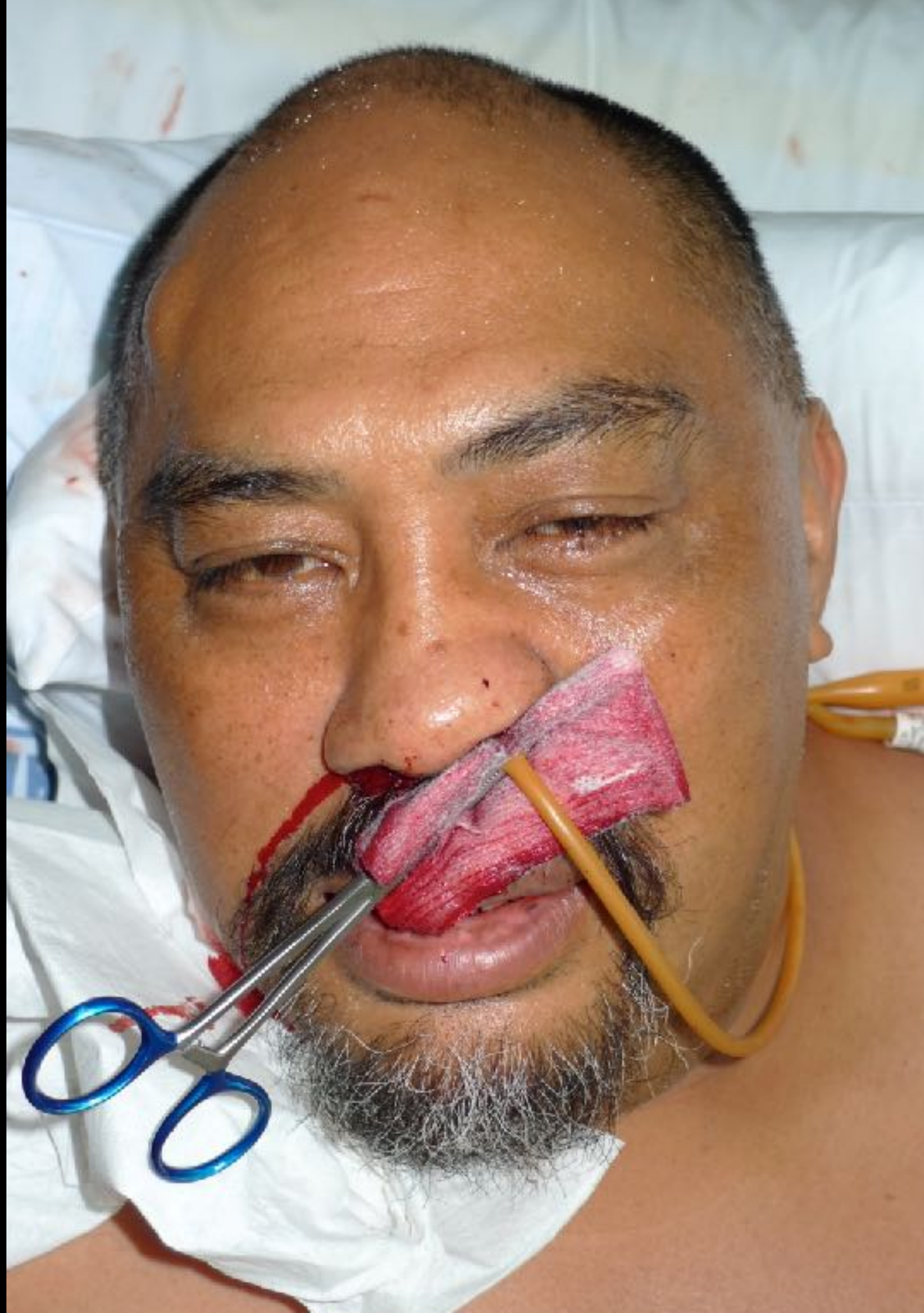

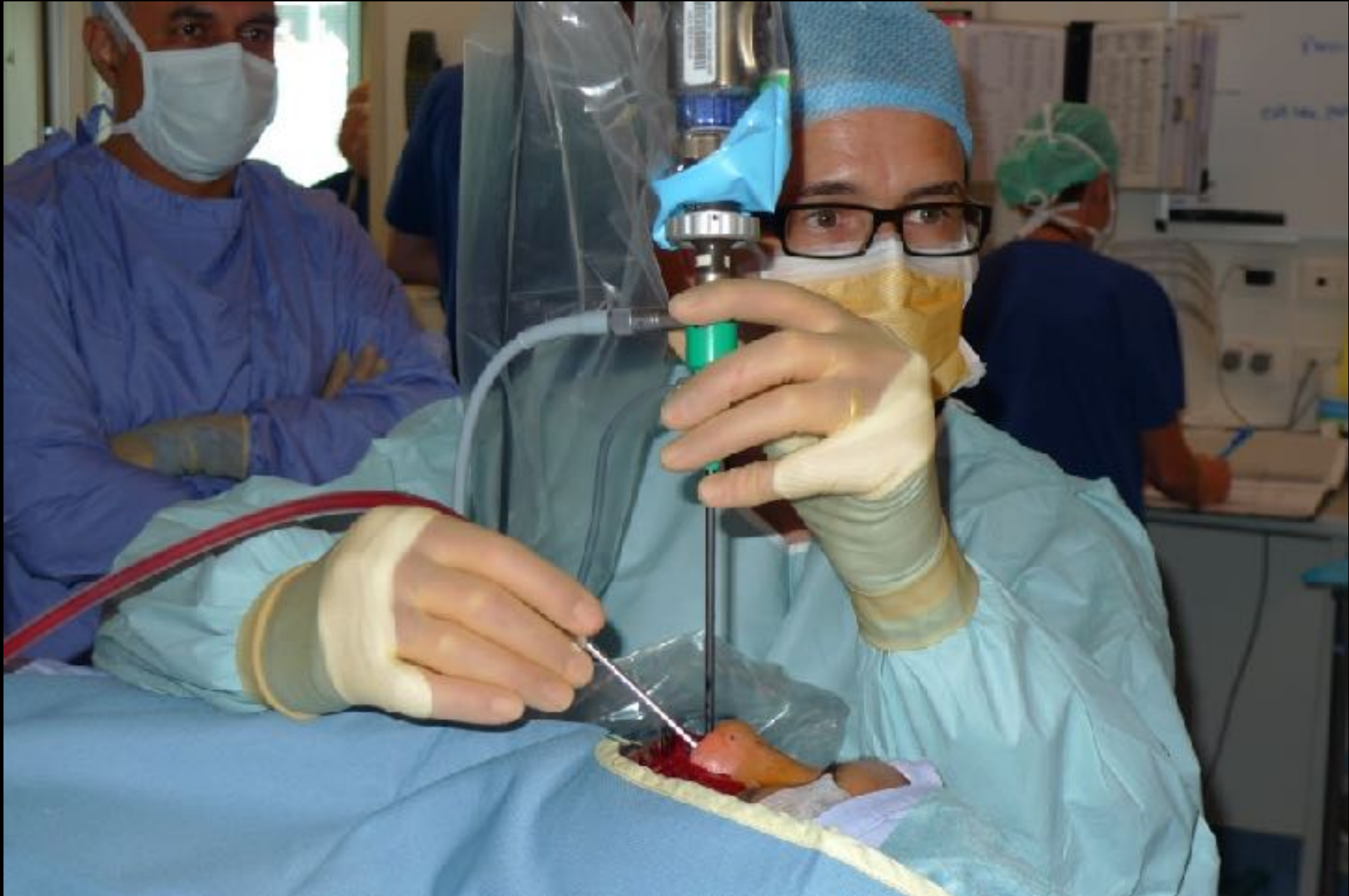# Septal blood supply



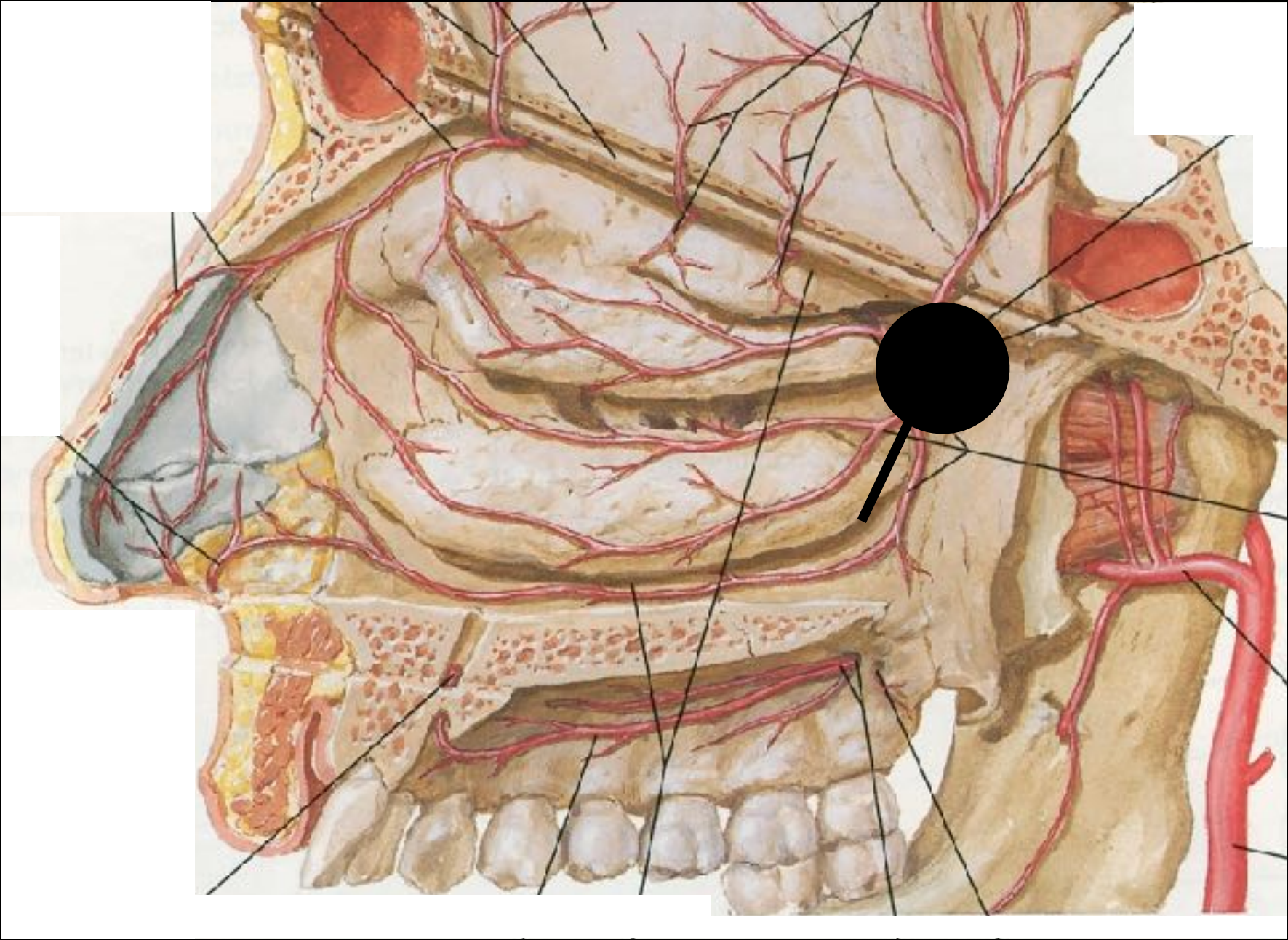


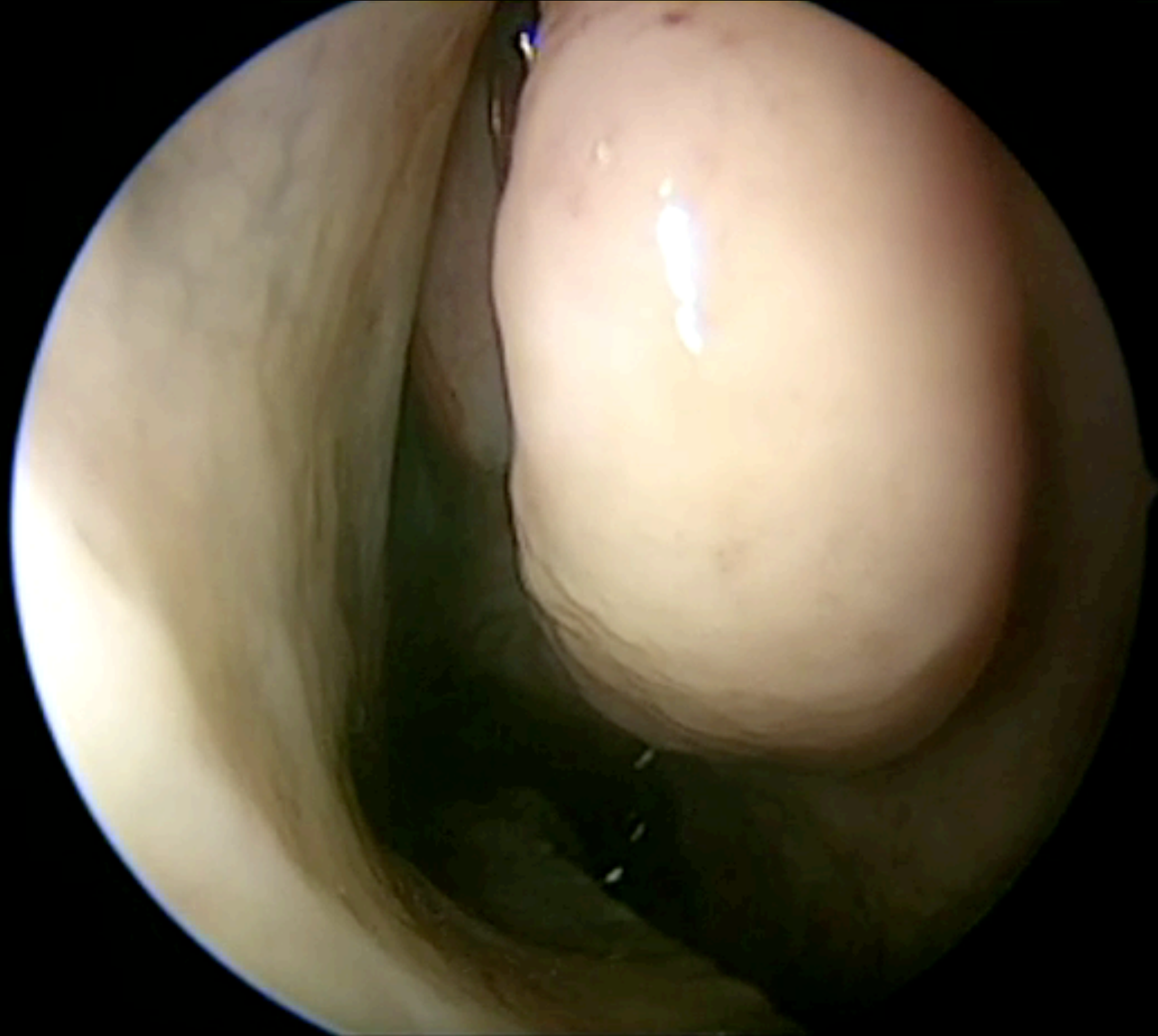




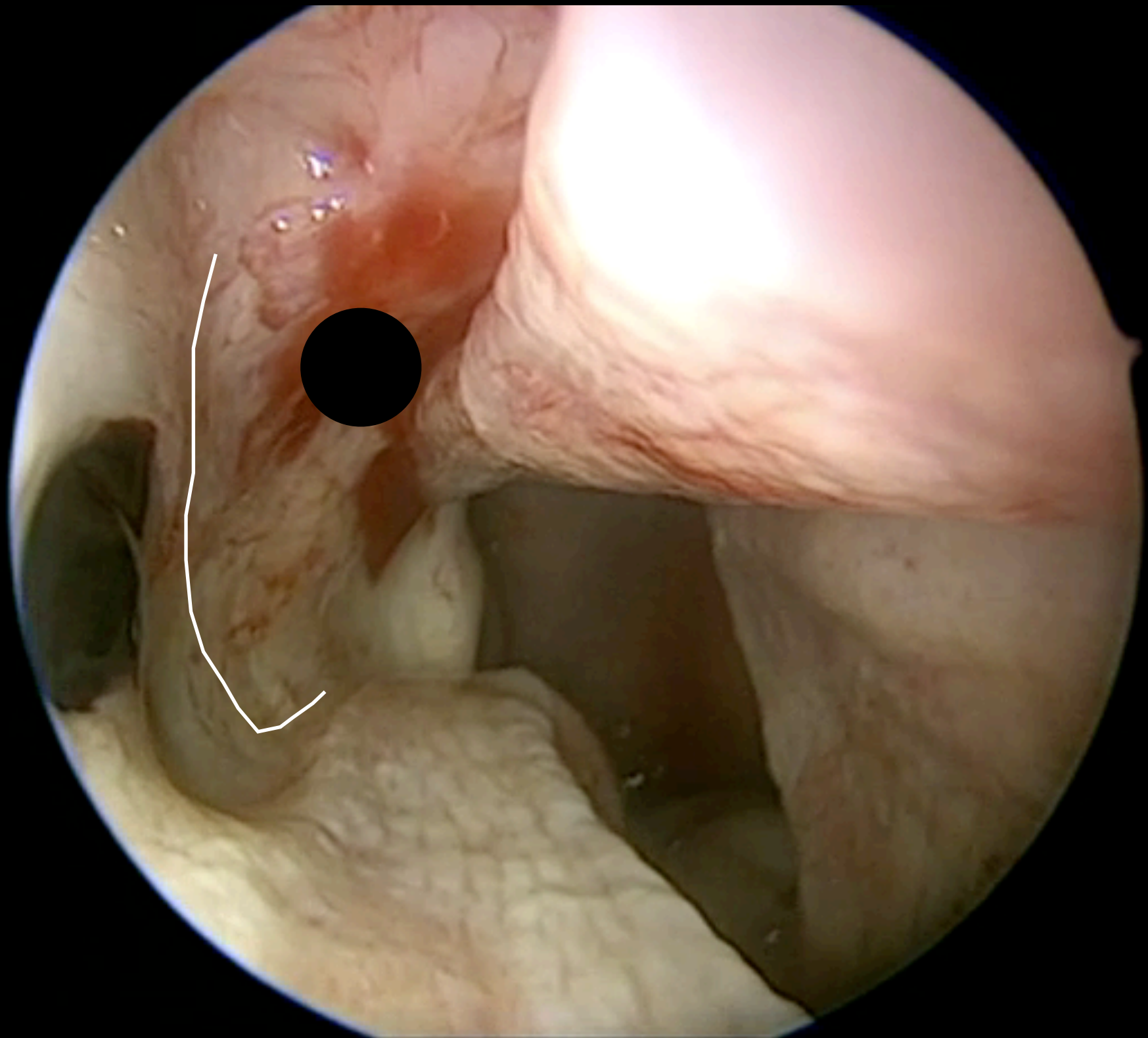


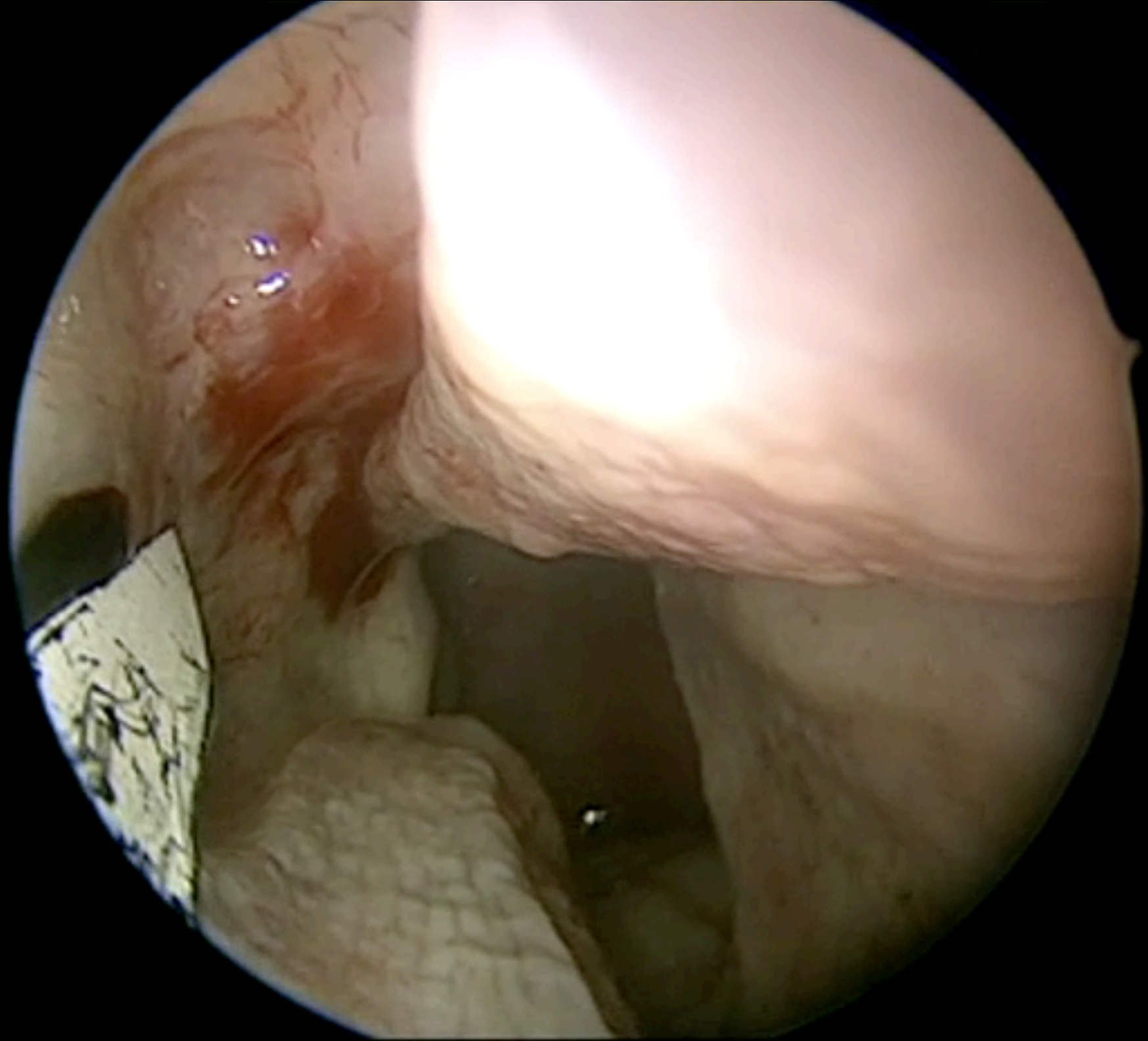


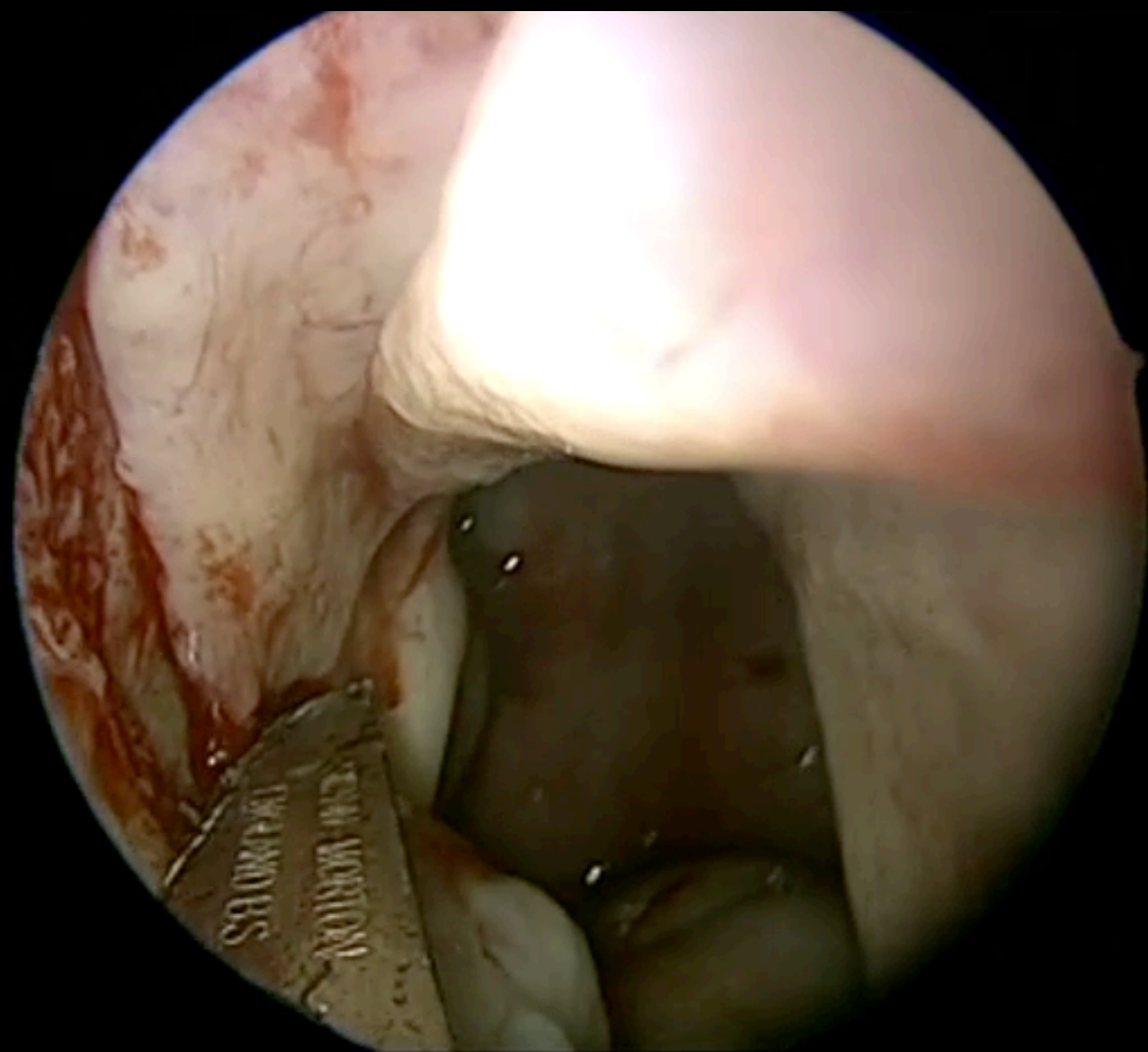




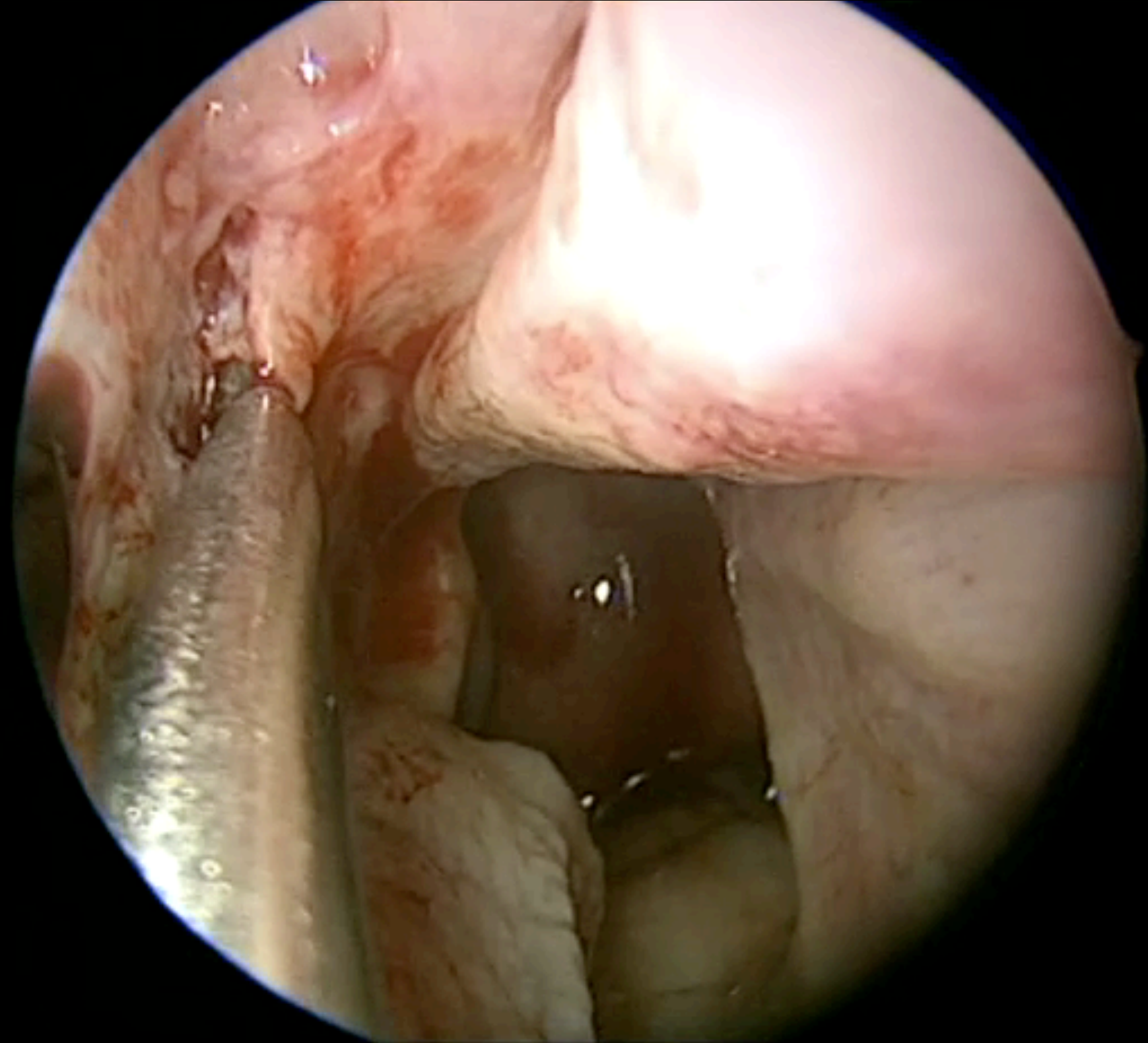




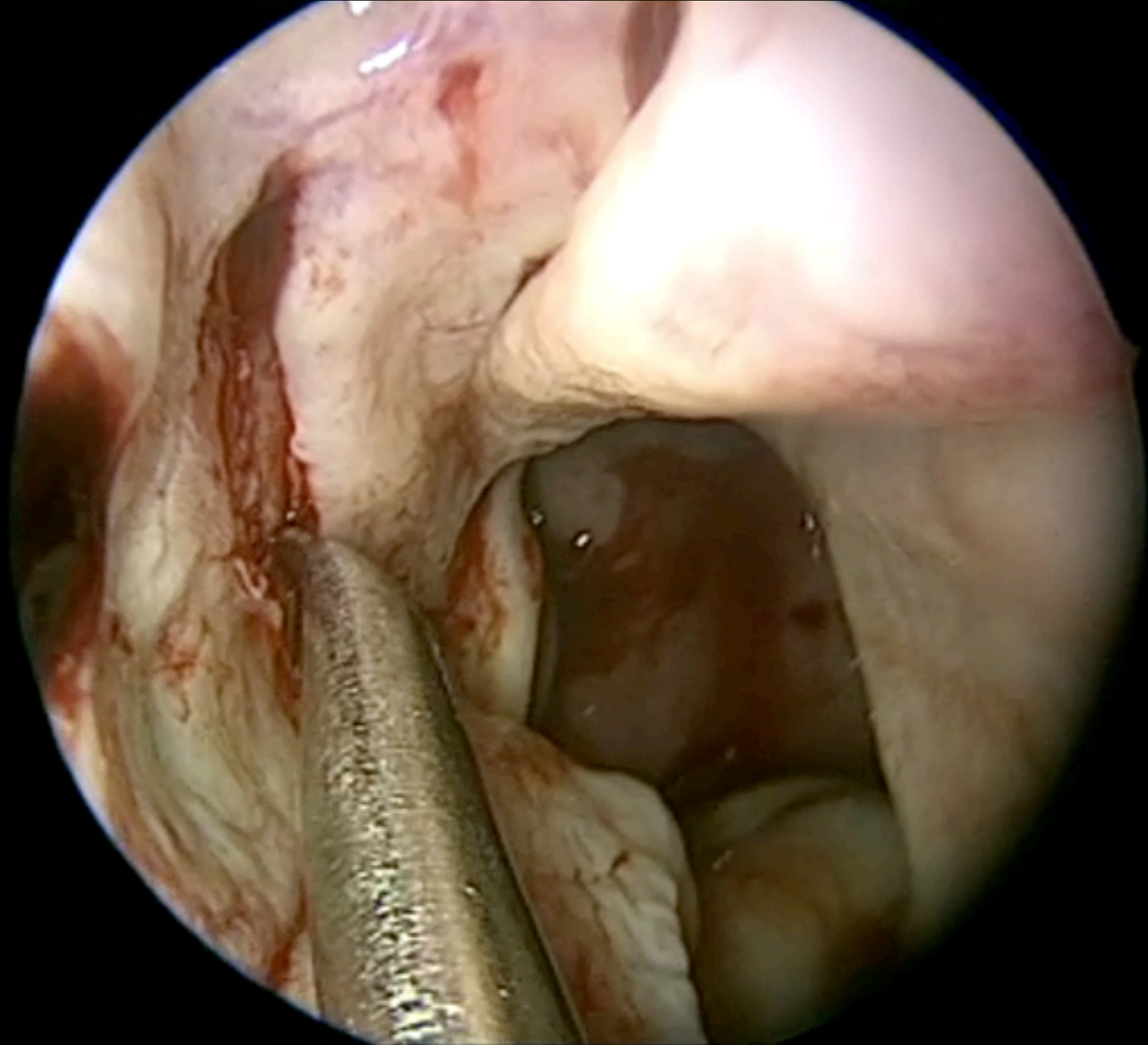


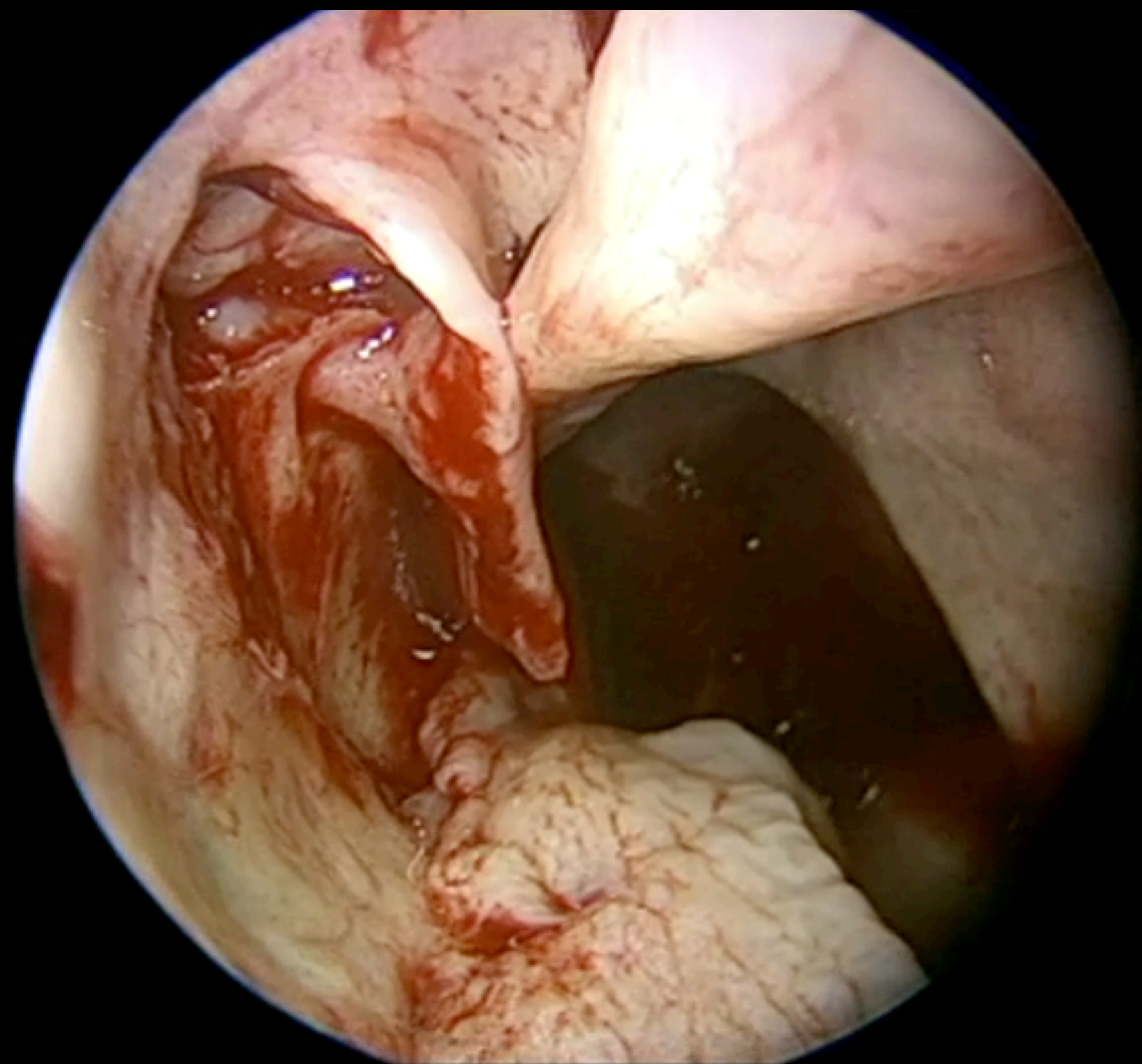




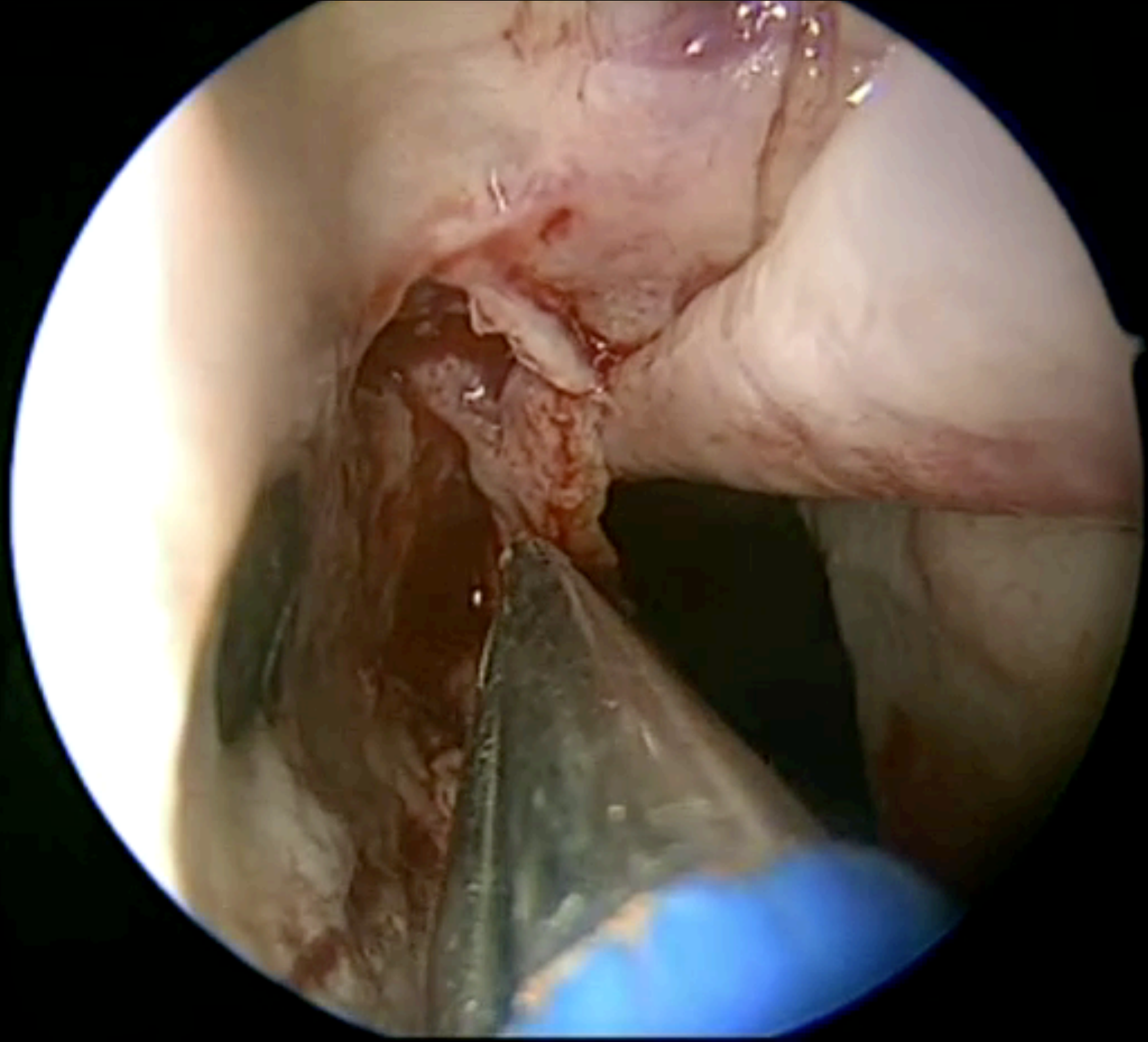


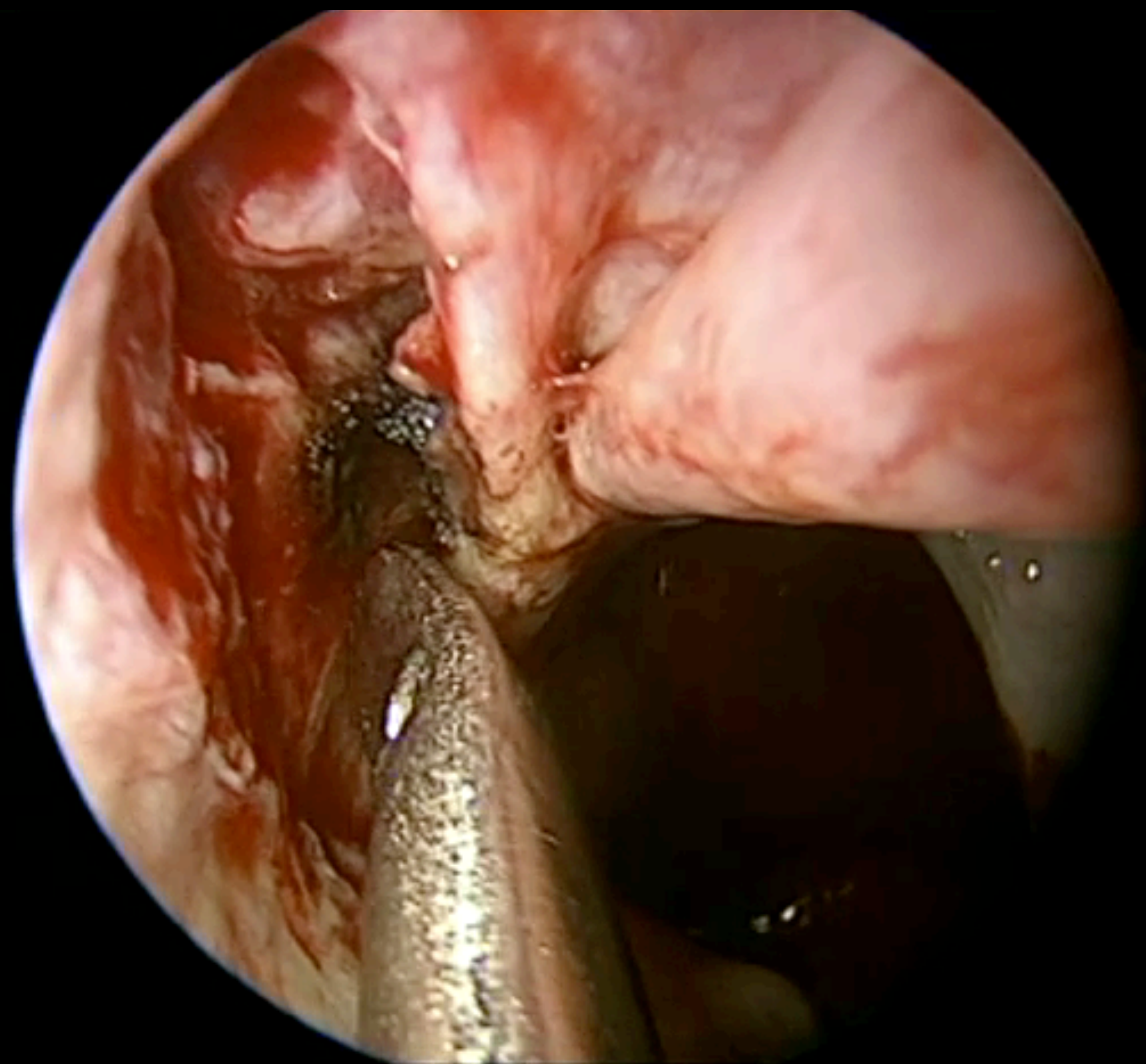




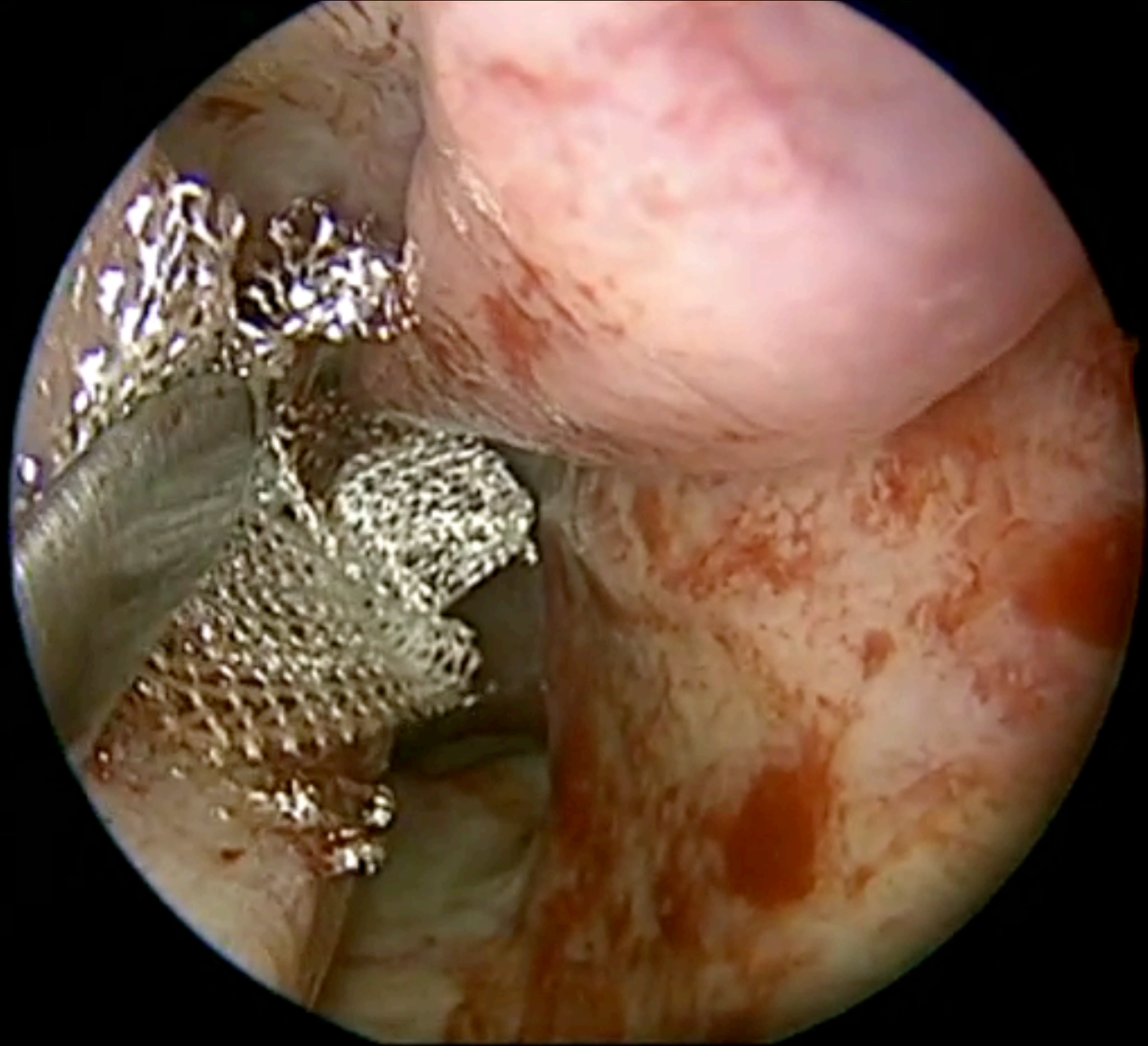










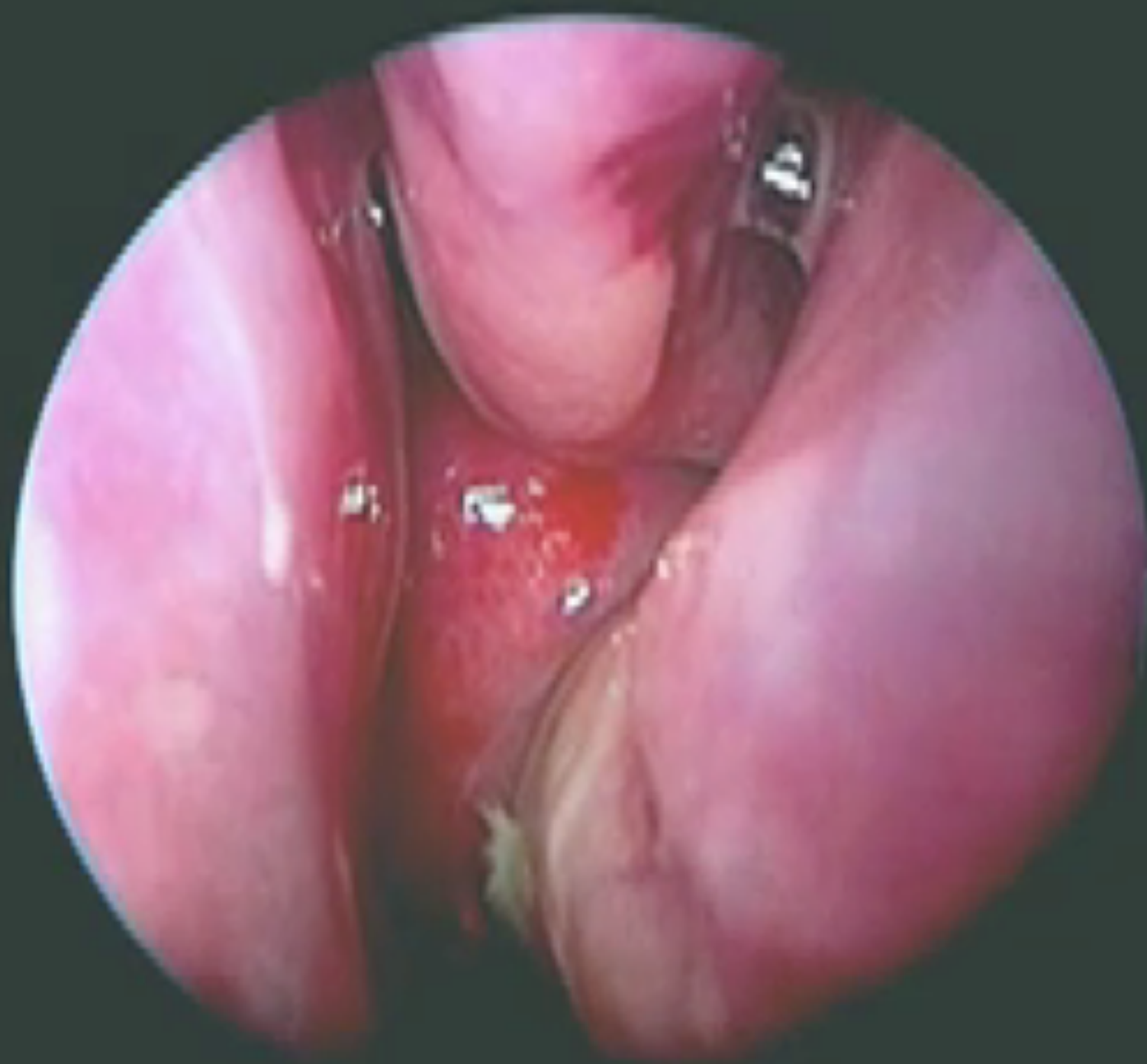


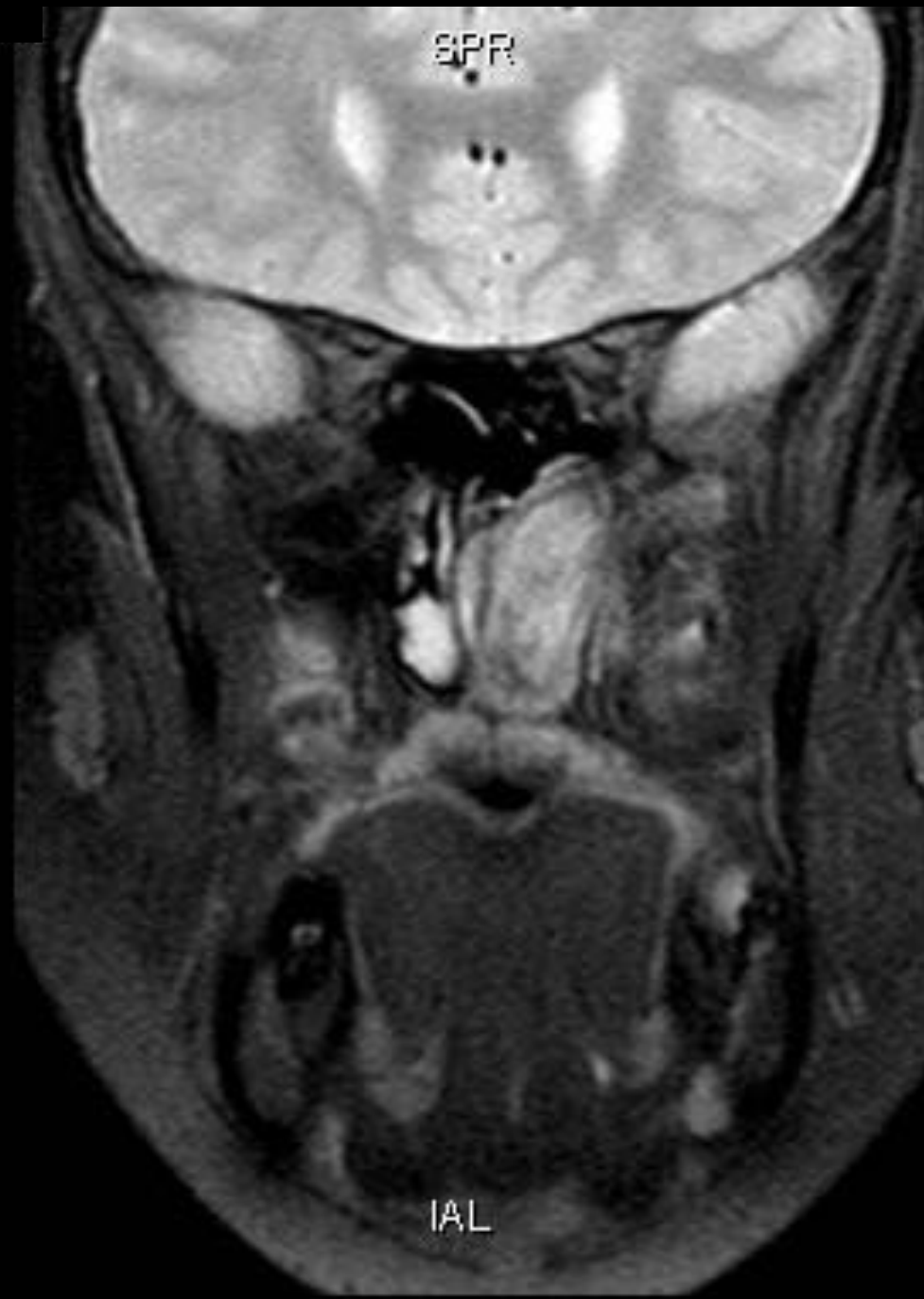# Case

14 year old boy

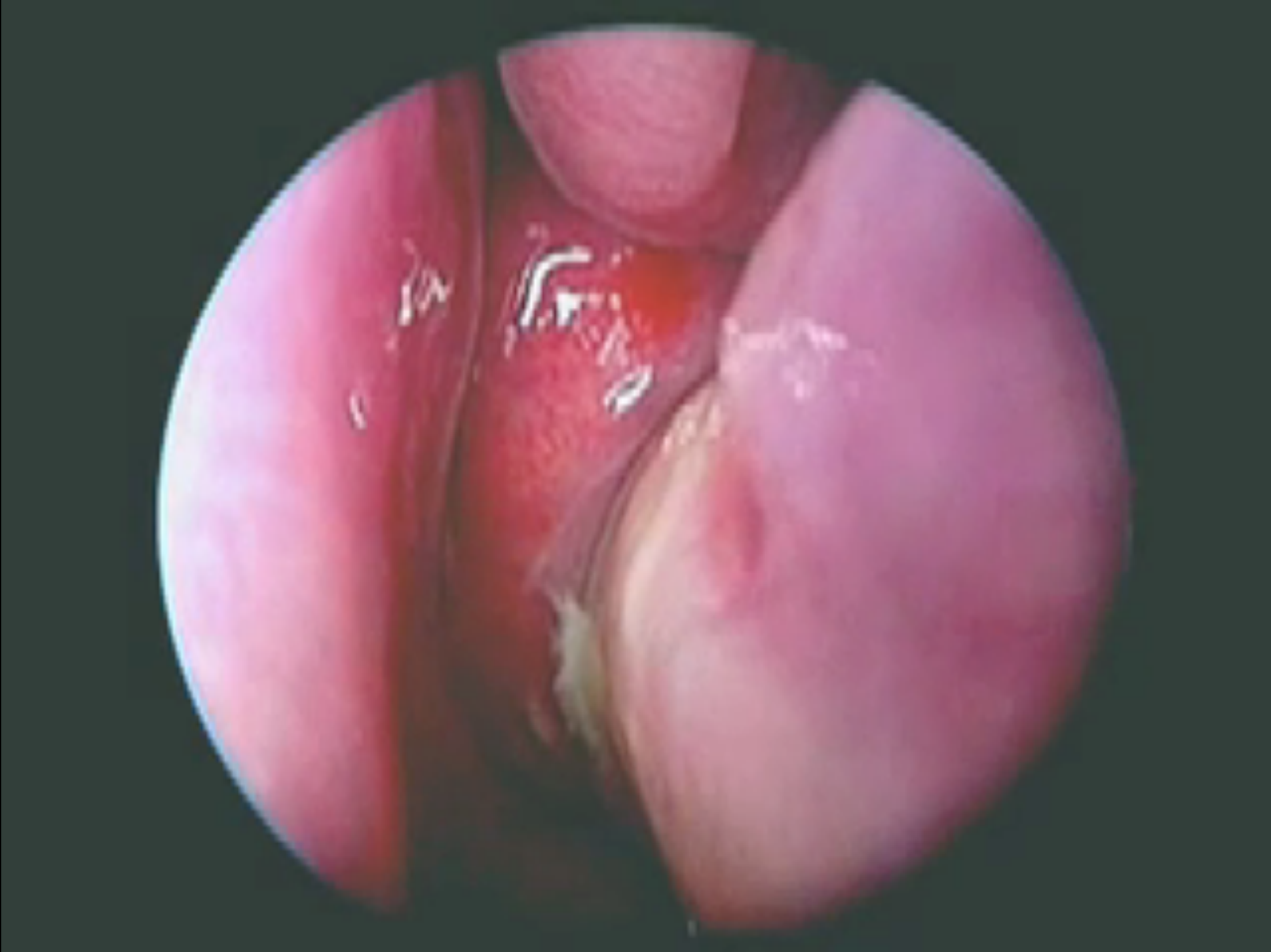
recurrent brisk left sided epistaxes 6/52

left sided nasal obstruction









nasal examination

otoscope

epistaxis

anterior - silver nitrate cautery

posterior - packing then endoscopic ligation